

Effect of Corn Oil, Flaxseed Oil and Black Seed Oil on Testicular Damage Induced by Lead Acetate in Albino Mice: A Histological Study

Doaa M. El-Nager¹ and Badr Abdullah Aldahmash^{2*}

¹College of Science, Arts and Education for Girls, Ain Shams University, Cairo, Egypt

²Medical Laboratory Department, College of Health Sciences, King Saud University, Riyadh, Saudi Arabia

Abstract.- Considering the established impact of lead as pollutant on human and animal health, the present study was initiated to investigate the potential use of corn oil, flaxseed oil and black seed oil to cure histological testicular damage induced by lead acetate in albino mice. The studies showed that lead acetate induced severe testicular damage represented by atrophy. The black seed oil however reduced the atrophy and degeneration of testicular tissue compared with those treated with flaxseed oil and corn oil.

Key words: Lead acetate, corn oil, flaxseed oil, black seed oil, testes.

INTRODUCTION

Lead is a ubiquitous environmental and industrial pollutant that has been detected in every facet of environmental and biological systems (Bokara *et al.*, 2008; Saryan and Zen, 1994). Lead acetate elicits toxic pathological changes in the testes, leading to its atrophy (Ghalberg and Brodas, 1981; Cullen *et al.*, 1984, Saxena *et al.*, 1984, 1986; Acharya and Mishra, 1995) disorganized epithelia, decreased sperm quality, altered sperm morphology, and low androgen levels (Hsu *et al.*, 1997; Alexander *et al.*, 1996). Several chelating agents that have been used to reduce the burden of the toxic effect of lead, have only added to the toxicity level. This has necessitated the search for therapeutic potential of various medicinal plants and herbs (Senapati *et al.*, 2001). Corn oil contains a significant amount of linolenic acid and high amounts of alpha- and gamma-tocopherols (vitamin E) that protect it from oxidative rancidity. Linoleic acid is a dietary essential that is necessary for integrity of the skin, cell membranes, the immune system, and for synthesis of icosanoids. Icosanoids are necessary for reproductive, cardiovascular, renal, and gastrointestinal functions and resistance to disease (Dupont *et al.*, 1990). Flaxseed, *Linum usitatissimum*, contains 32 to 45% of its mass as oil

of which 51 to 55% is alpha-linolenic acid (18:3 n-3 omega-3 fatty acid), it may have beneficial effects on health and in control of chronic diseases it has anticancer effects, antiviral and bactericidal activity, anti-inflammatory effect, ion reduction (Mantzioris *et al.*, 1994; Abdel-Moneim *et al.*, 2010b; Craig, 1999). Black seed (*Nigella sativa*) has been used in many Middle Eastern countries as a natural remedy (Swamy and Tan, 2000). Seeds contain 36-38% fixed oils, proteins, alkaloids, saponin and 0.4-2.5% essential oil (Ali and Blunden, 2003). Black seed components display a remarkable array of biochemical, immunological and pharmacological actions (Agarwal *et al.*, 1979; Boulos 1983; Al-Hader *et al.*, 1993; Houghton *et al.*, 1995; Haq *et al.*, 1999). Therefore, the present work was done to investigate the hazardous effects of lead as environmental pollutants on testes and how can natural products as oils to cure testicular damage induced by lead acetate and also to carry out comparison between effects of corn oil, flaxseed oil and black seed oil to reduce testicular damage induced by lead acetate.

MATERIALS AND METHODS

Animals

Adult albino mice, 20-25 g, were obtained from animal facility of King Saud University and maintained in wire cages at 25±1°C with an equal dark and light illumination cycle. They were provided with tap water and balanced diet *ad*

* Corresponding author: dr_badr211@hotmail.com
0030-9923/2013/0004-1083 \$ 8.00/0
Copyright 2013 Zoological Society of Pakistan

libitum. The experiments were approved by the state authorities and followed Saudi Arabian rules of animal protection.

Procedure adopted

Animals were randomly allocated to five groups of six mice each. Group 1 which served as a control received 0.1ml saline orally followed by *i.p.* administration of 100 µl of saline after one hour. Group 2 received daily *i.p.* injection of lead acetate (20 mg/kg body wt) (Ito *et al.*, 1985; Abdelmoneim *et al.*, 2010a), for 5 days. The remaining animals of groups 3, 4 and 5 were injected 20 mg/kg lead acetate. One hour after the treatment, group 3 received oral administration of 1000 mg/kg corn oil (Afia international company, Riyadh, Saudi Arabia), group 4 received 1000 mg/kg flaxseed oil (Wadi Al-Nahil Company, Saudi Arabia) and group 5 received 1000 mg/kg black seed oil (Wadi Al-Nahil, Saudi Arabia), respectively. After 24 h of the last *i.p.* injection of lead acetate and oils, the animals of all groups were killed by ether and testes samples were collected.

Testes were collected and fixed in 10% neutral buffered formalin. Following fixation, specimens were dehydrated, embedded in wax, and then sectioned to 5 µm thickness. Sections were stained with hematoxylin and eosin.

RESULTS

Control testes

Figure 1 show typical histological structure of testes, in which convoluted seminiferous tubules, thick basal lamina and 3-4 layers of smooth muscle cells can be seen (Fig. 1a). The insides of the tubules are lined with seminiferous epithelium, which consists of two general types of cells: spermatogenic cells and Sertoli cells. Different cells of spermatogenic cells appeared in the tissue, spermatogonia these are the initial germ cells lying directly on the basement membrane. A large number of primary spermatocytes is always visible, which lie in the cell layer luminal to the spermatogonia. They appear larger than spermatogonia, secondary spermatocytes which are smaller than primary spermatocytes. Spermatids, which lie in the luminal part of the seminiferous epithelium, that appeared in

two forms the first was small, rounded with central nucleus, whereas, the second elongated with eccentric nucleus. Leydig cells were located in the interstitial tissue between the convoluted seminiferous tubules, Leydig cells occur in clusters, which are variable in size (Fig. 1b).

Effect of lead acetate

Figure 2 shows histological structure of testes of lead acetate treated mice. The majority of seminiferous tubules were shrunken and interstitial tissue was degenerated (Fig. 2a). wavy outline of seminiferous tubule and irregular basement membrane were observed, seminiferous tubule showed wide necrotic areas, small spermatogonia and few number of spermatocytes were seen, lumen was filled with cell remnants, distorted spermatids and rarely mature sperm, severe destruction in the interstitial tissue was observed (Fig. 2b). Figure 2c showed degenerative changes marked by wide necrotic areas in the seminiferous tubule, sparse spermatocytes with large and dark stained nuclei were appeared while other spermatocytes showed pyknotic nuclei, absence of spermatids and mature sperms and ill-defined sertoli cells were noticed. The irregular basement membranes of seminiferous tubules were lined with one or two layers of small acidophilic cells with dark nuclei and several layers of degenerated cells, different germ cells especially mature sperms were not seen, in the seminiferous tubule whereas, hyaline necrotic areas were observed (Fig. 2d). The interstitial cells of leydig were also reduced in number and their characteristic tendency of clumping together to form clusters was also reduced. All these features were suggestive of atrophy of the testes.

Effect of corn oil on the lead acetate treated mice

Testes of the mice received ip injection of lead acetate was followed by oral administration of corn oil revealed scarcely reduced testes injury compared to that treated with lead acetate only. General structure of testes still showed abnormal feature of irregular seminiferous tubules with degenerative changes. The outline of some seminiferous tubules appeared straight but thick. Multinucleated giant cells were demonstrated within the lumen of the seminiferous tubule. They exhibited

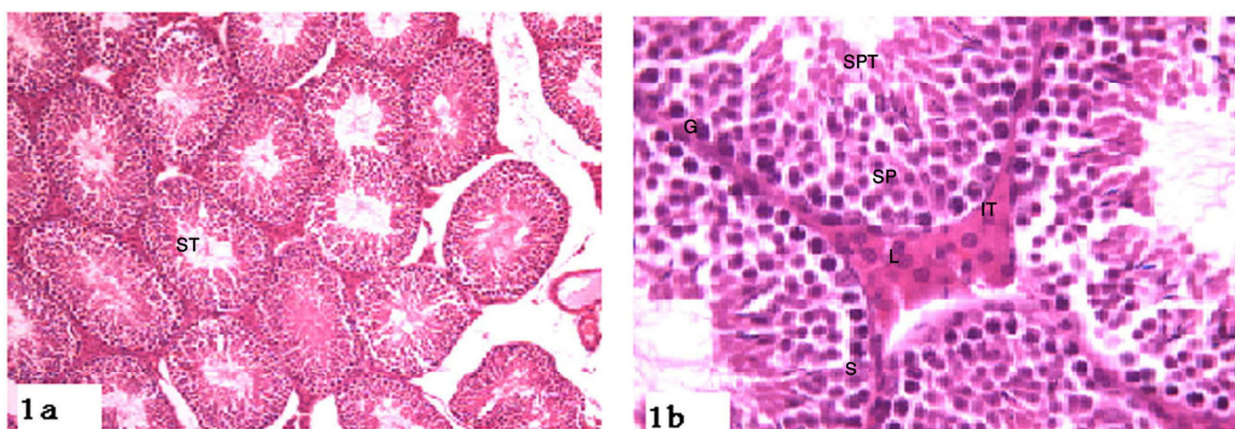


Fig. 1. Histological structure of control mouse testes showing a, normal architecture: control testes with normal seminiferous tubules (ST); b, normal structure of sperm stages, spermatogonia (G), sertoli cell (S), spermatocytes (SP), spermatids (SPT) normal interstitial tissue (IT) with clusters of leydig cells (L). Magnification: a, 100x, b, 40 x. Stain hematoxylin –eosin.

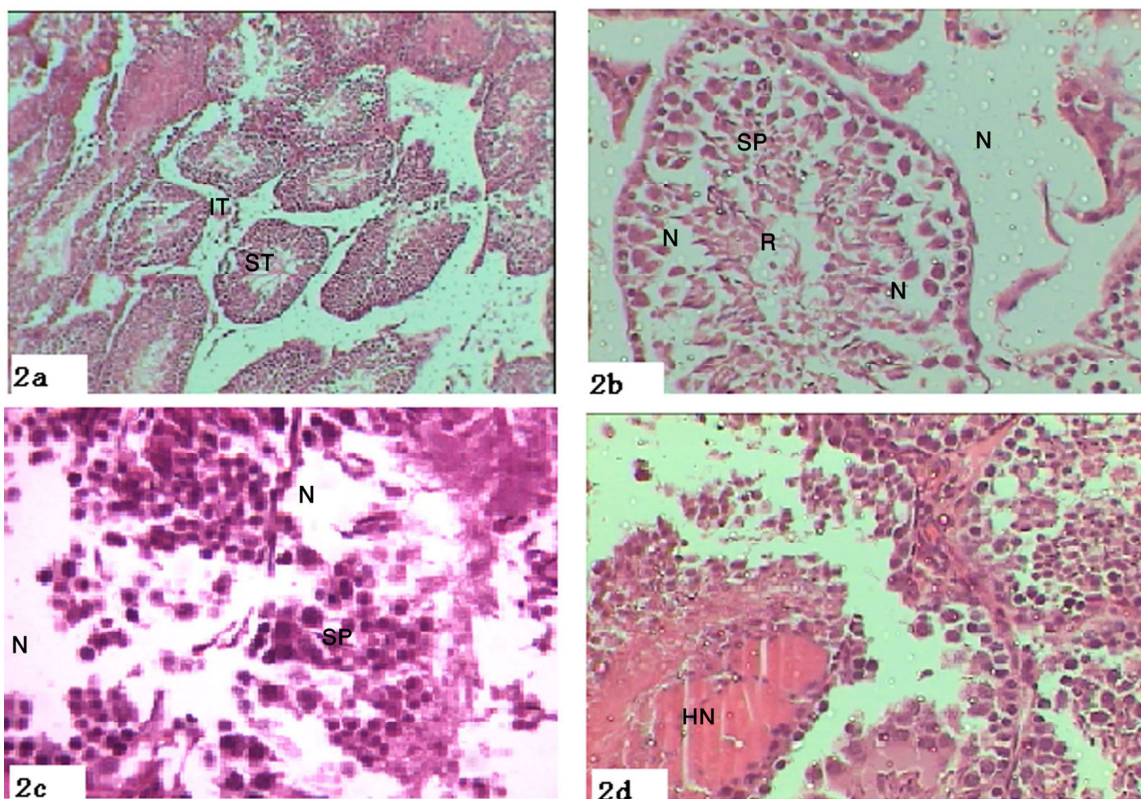


Fig. 2. Lead acetate induced testes injury in albino mice a, abnormal testes architecture, destructed and shrunken seminiferous tubules and degenerated interstitial tissue; b, wavy outline of seminiferous tubule, necrotic areas (N), few number of spermatocytes (SP), cell remnants in the lumen (R); c, necrotic areas in the seminiferous tubule, sparse spermatocytes; d, several layers of degenerated cells in seminiferous tubule, hyaline necrotic area, reduction in number of leydig cells. Magnification: a, 100x, b, 400 x. Stain. Hematoxylin-eosin

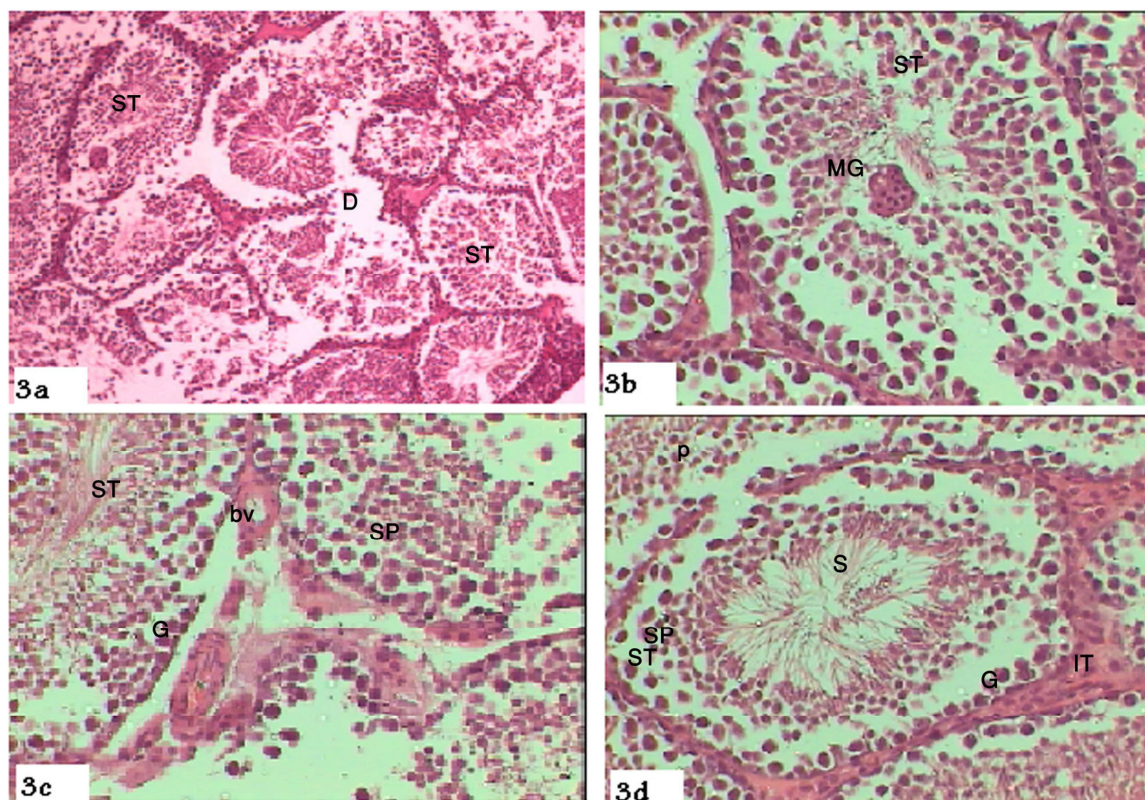


Fig. 3. Corn oil scarcely reduced toxicity induced by lead acetate a, irregular seminiferous tubules (ST), degenerated areas (D); b, seminiferous tubule (ST) with multinucleated giant cell in the lumen (MG); c, germ cells (G), different spermatocysts (SP), spermatids (ST), destructed interstitial tissue, collapsed and sparse blood vessels (bv), (d mag. x-400) thick but straight outline of seminiferous tubule (ST), lumen filled with mature sperm (S), small cells with pyknotic nuclei (p), interstitial tissue (IT). Magnification: a, 100x, b, c, d, 400x. Stain: Hematoxylin-eosin.

acidophilic cytoplasm and number of rounded nuclei, it may be formed due to fusion of rounded spermatids (Figs. 3a,b). Different germ cells was obvious, spermatids and mature appeared to some extent in the seminiferous tubules, sections demonstrated different sizes and shapes of spermatocytes, some of them were large in size and contained darkly stained nuclei, others were small and had pyknotic nuclei and others appeared completely degenerated. The sertoli cells were defined but looked faintly, the blood vessels in the interstitium were sparse and collapse. The interstitial leydig cells were prominent in whereas, the interstitial tissue looked degenerated in some areas and thickened in other areas (Figs. 3c, d).

Effect of flex seed soil on the lead acetate treated mice

Administration of flaxseed oil to the lead

acetate treated mice showed significant reduction in testes injury compared to the previous treated testes, seminiferous tubules were filled with different germ cells, necrotic areas was reduced, prominent sertoli cells appeared (Figs. 4a,b) some seminiferous tubules with thick outline were shrunken and surrounded by congested interstitial tissue with number of leydig cells, it was obvious that thickness in the interstitial tissue was induced due to the precipitation of fibers (Figs. 4c, d).

Effect of black seed oil on the lead acetate treated mice

The administration of blackseed oil to the lead acetate treated mice showed obvious reduction in testes injury compared to the previous groups. Most of the seminiferous tubules were more or less similar to those of the normal control group, seminiferous tubules looked more healthy with

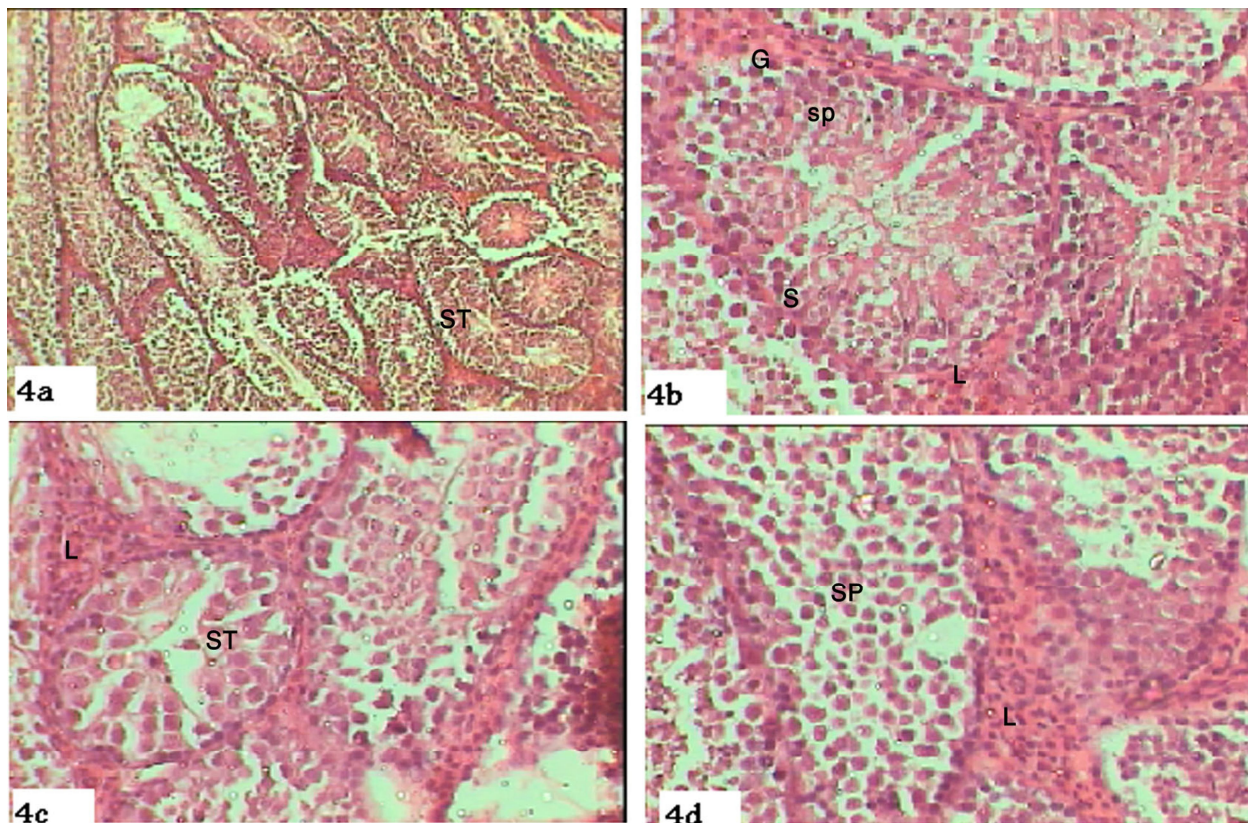


Fig. 4. Effect of flaxseed oil significantly reduced the toxicity induced by lead acetate; a, seminiferous tubules (ST), b, spermatogonia (G) and spermatocytes (SP), prominent sertoli cell (S); c, shrunken seminiferous tubule (ST) with thick outline, clusters of leydig cells (L); d, different stages of spermatocytes (SP), wide interstitial tissue filled with clusters of leydig cells (L) Magnification: a, 100x, b, c, d, 400x. Stain: Hematoxylin-eosin.

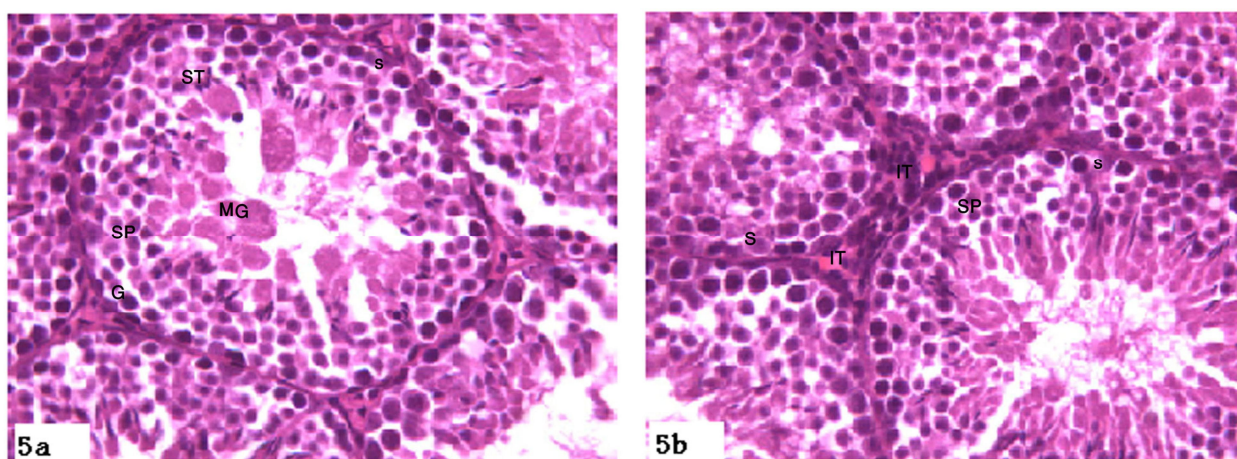


Fig. 5. Effect of black seed oil on black seed oil reduced toxicity induced by lead acetate; a, b, healthy seminiferous tubules (ST), spermatogonia (G), different spermatocytes (SP), multinucleated giant cells (MG), sertoli cell (S), normal interstitial tissue (IT). Magnification: a, b, 400x. Stained Hematoxylin & eosin.

normal outline and normal interstitial tissue with leydig cells. Respectively normal germ cells, sertoli cells and different spermatocytes were obvious, some seminiferous tubules contained some giant cells of spermatids fusion (Figs. 5a.b).

DISCUSSION

Lead is a ubiquitous environmental and industrial pollutant that has been detected in every facet of environmental and biological systems (Kiran *et al.*, 2008). The toxicity of lead remains a matter of public health concern (Duzgoren-Aydin, 2007) due to its pervasiveness in the environment and the awareness about its toxic effects (Saleh *et al.*, 2003). The results of the present work showed that lead exposure caused testes atrophy manifested by distorted and shrunk seminiferous tubules with thick and irregular membrane, degenerated spermatogonia and spermatocytes, absence of spermatids and mature sperm and reduction in the interstitial cells of leydig, this could be due to distribution of lead in the seminiferous tubules via blood stream and then absorbed lead caused mechanism of toxicity in the seminiferous tubules. These findings are in agreement with Abdel-Moneim *et al.* (2010b) who reported that lead exposure caused progressive vascular, tubular and interstitial testicular damage. These results also agreed with the findings of Arora *et al.* (2004), Giuliani *et al.* (2005) and Maklouf *et al.* (2008) who proved that exposure of lead induced testes injury represented by apoptotic changes in most of the germ cells and thickness in the basement membrane of the seminiferous tubules might be result from increase in the amount of collagenous fibers that could result from either over production of collagen fibers by fibroblasts or decrease the rate of collagen phagocytosis. Corn oil contains linoleic acid and significant amount of alpha and gamma tocopherols (vitamin E) that protect from oxidative rancidity (Dupont *et al.*, 1990). The present findings revealed that corn oil scarcely reduced lead acetate toxicity represented by abnormal feature of seminiferous tubules and presence of giant multinucleated cells within the lumen.

Multinucleated cells were formed of fusion of

two or more spermatids contained two or more nuclei (Maklouf *et al.*, 2008). Currently, the increasing interest in the potential health benefits of estrogenic plant compounds, such as flaxseed, is leading to greater daily consumption. Some of the interest in flaxseed is attributed to its high content of the polyunsaturated fatty acid, α -linolenic acid and its high content of the lignan precursor. Babu *et al.* (2000). In full agreement with Abdel-Moniem *et al.* (2010b) who stated that degenerative changes caused by lead acetate were significantly rescued after treatment of rats with flaxseed oil that the present results ran with, flaxseed oil significantly reduced lead acetate toxicity manifested by more or less healthy seminiferous tubules filled with different germ cells and prominent sertoli cells. *Nigella sativa* (Black seed, BS) has been used to promote health and fight disease for centuries (Corder *et al.*, 2003), moreover Al-Ghamdi (2003) reported that *Nigella sativa* oil possesses hepatoprotective effects in some models of liver toxicity. However, it is *N. sativa* seeds that are used in the treatment of liver ailments in folk medicine rather than its oil. Currently, the present results proved that black seed oil had valuable effect against lead toxicity that caused testes injury in mice stated by healthy seminiferous tubules with normal out line and normal interstitial tissue in between.

It was obvious from the overall results that lead as environmental pollutants had hazardous effects on health, it caused severe pathological changes on testes, it was found that some natural products as natural oils, flaxseed oil and black seed oil could reduce pathological changes induced by lead acetate, whereas corn oil could not reduce these changes.

REFERENCES

- ABDEL-MONEIM, A., DKHIL, M. AND AL-QURAIISHY, S., 2010a. The redox status in rats treated with flaxseed oil and lead-Induced hepatotoxicity. *Biol. Trace Element Res.*, **143**: 457-467.
- ABDEL-MONEIM, A., DKHIL, M. AND AL-QURAIISHY, S., 2010b. Protective role of flaxseed oil against lead acetate induced oxidative stress in testes of adult rats. *Afr. J. Biotech.*, **9**:7216-7223
- ACHARYA, U.R. AND MISHRA, P., 1995. Lead induced histopathological changes in the testes of Swiss mice.

- Adv. Biosci.*, **14**:37–44.
- AGARWAL, R., KHARYA, M.D. AND SHRIVASTAVA, R., 1979. Antimicrobial and antihelminthic activities of the essential oil of *Nigella sativa* Linn. *Ind. J. exp. Biol.*, **17**: 1264-1265.
- AL-GHAMD, I., 2003. Protective effect of *Nigella sativa* seeds against carbon tetrachloride-induced liver damage. *Am. J. Chinese Med.*, **31**: 721–728.
- AL-HADER, A., AQEL, M. AND HASAN, Z., 1993. Hypoglycemic effect of the volatile oil of *Nigella sativa* seeds. *Int. J. Pharmacol.*, **31**: 96-100.
- ALI, B.H. AND BLUNDEN, G., 2003. Pharmacological and toxicological properties of *Nigella sativa*. *Phytother. Res.*, **17**: 299-305.
- ARORA, P.D., GLOGAUER, M., KAPUS, A., KWIATKOWSKI, D.J. AND MCCULLOCH, C.A., 2004. Gelsolin mediates collagen phagocytosis through a rac-dependent step. *Mol. Biol. Cell*, **15**: 588-599.
- BABU, U.S., MITCHELL, G.V., WIESENFELD, P., JENKINS, M.Y. AND GOWDA, H., 2000. Nutritional and hematological impact of dietary flaxseed and defatted flaxseed meal in rats. *Int. J. Fd. Sci. Nutr.*, **51**: 109-117.
- BOKARA, K., BROWN, E., MCCORMICK, R., YALLAPRAGADA, P., RAJANNA, S. AND BETTAIYA, R., 2008. Lead-induced increase in antioxidant enzymes and lipid peroxidation products in developing rat brain. *Biometals*, **21**:9-16.
- BOULOS, L., 1980. *Medicinal plants of North Africa*. Reference Publications Inc., Michigan.
- DUPONT, J., WHITE, P., CARPENTER, M., SCHAEFER, E., MEYDANI, S, ELSON, C., WOODS, M. AND GORBACH, S., 1990. Food uses and health effects of corn oil. *J. Am. Coll. Nutr.*, **9**: 438-470.
- CULLEN, M.R., KAYNE, R.D. AND ROBINS, J.M., 1984. Endocrine and reproductive dysfunction in men associated with occupational inorganic lead intoxication. *Arch. environ. Hlth.*, **39**: 431–440.
- CORDER, C., BENGHUZZI, H., TUCCI, M. AND CASON, Z., 2003. Delayed apoptosis upon the treatment of Hep-2 cells with black seed. *Biomed. Sci. Instrum.*, **39**:365-370
- CRAIG, W.J., 1999. Health-promoting properties of common herbs. *Am. J. clin. Nutr.*, **70**: 491S-499S
- DUZGOREN-AYDIN, N.S., 2007. Sources and characteristics of lead pollution in the urban environment of Guangzhou. *Sci. Total Environ.*, **385**: 182-195.
- GIULIANI, R., BETTONI, F., LEALI, D., MORANDINI, F., APOSTOLI, P., GRIGOLATO, P., CESANA, B.M. AND ALEO, M.F., 2005. Focal adhesion molecules as potential target of lead toxicity in NRK-52E cell line. *FEBS Lett.*, **579**: 6251-6258.
- HAQ, A.,AL-TUFAIL, P., RAMA, L. AND AL-SEDAIRY, S., 1999. Immunomodulatory effect of *Nigella sativa* proteins fractionated by ion exchange chromatography. *Int. J. Immunopharmacol.*, **21**: 283-295.
- HOUGHTON, P.J., ZARKA, R., DE LAS HERAS, B. AND HOULT, J., 1995. Fixed oil of *Nigella sativa* and derived thymoquinone inhibit eicosanoid generation in leukocytes and membrane lipid peroxidation. *Planta Med.*, **61**: 33-36.
- ITO, Y., NIIYA, Y., KURITA, H., SHIMA, S. AND SARAI, S., 1985. Serum lipid peroxide level and blood superoxide dismutase activity in workers with occupational exposure to lead. *Int. Arch. Occup. environ. Hlth.*, **56**:119-127.
- KIRAN, B., ERIKA, B., RASHIDI, M., PRABHAKARA, R., SHARADA, R., RAJANNA, B., 2008. Lead-induced increase in antioxidant enzymes and lipid peroxidation products in developing rat brain. *Biometals*, **21**: 9-16.
- MAKHLOUF, M., ELDIEN, H., ZAGLOUL, D., ABU DIEF, E. AND ABD ELHALIEM, N., 2008. The effect of lead acetate on testicular structure and protective effect of vitamin e in adult albino rat. *Egypt. J. Histol.*, **31**: 406-418.
- MANTZIORIS, E., JAMES, M.J., GIBSON, R.A. AND CLELAND, L.G., 1994. Dietary substitution with an alpha-linolenic acid-rich vegetable oil increases eicosapentaenoic acid concentrations in tissues. *Am. J. clin. Nutr.*, **59**: 1304-1309.
- SALEH, A.M., VIJAYASARATHY, C., MASOUD, L., KUMAR, L., SHAHIN, A. AND KAMBAL, A., 2003. Paraoxon induces apoptosis in EL4 cells via activation of mitochondrial pathways. *Toxicol. appl. Pharmacol.*, **190**: 47-57.
- SENAPATI, S.K., DEY, S., DWIVEDI, S.K. AND SWARUP, D., 2001. Effect of garlic (*Allium sativum* L.) extract on tissue lead level in rats. *J. Ethnopharmacol.*, **76**: 229-232.
- SARYAN, L.A. AND ZEN, Z.C., 1994. Lead and its compounds. In: *Occupational medicine* (eds. O.B. Dickerson, C. Zenz and E.P. Horvath). 3rd ed. Mosby Inc., Orlando, Florida, USA. pp. 506-541.
- SAXENA, D.K., LAL, B., MURTHY, R.C. AND CHANDRA, S.V., 1984. Lead induced histological changes in testes of rats. *Ind. Hlth.*, **22**: 225–260.
- SAXENA, D.K., HUSAIN, T., LAL, B. AND CHANDRA, S.V., 1986. Lead induced testicular dysfunction in weaned rats. *Ind. Hlth.*, **22**:105–109.
- SWAMY, S.M. AND TAN, B.K., 2000. Cytotoxic and immunopotentiating effects of ethanolic extract of *Nigella sativa* L. seeds. *J. Ethnopharmacol.*, **70**: 1-7.

(Received 9 January 2013; revised 25 July 2013)